

# Myocardial Infarction with Unique Complication

Michael Zarrella PGY1, Michelle Dellalana PGY1, Ashish Arora MD

Department of Medicine, St. Mary's Hospital, Waterbury, Connecticut

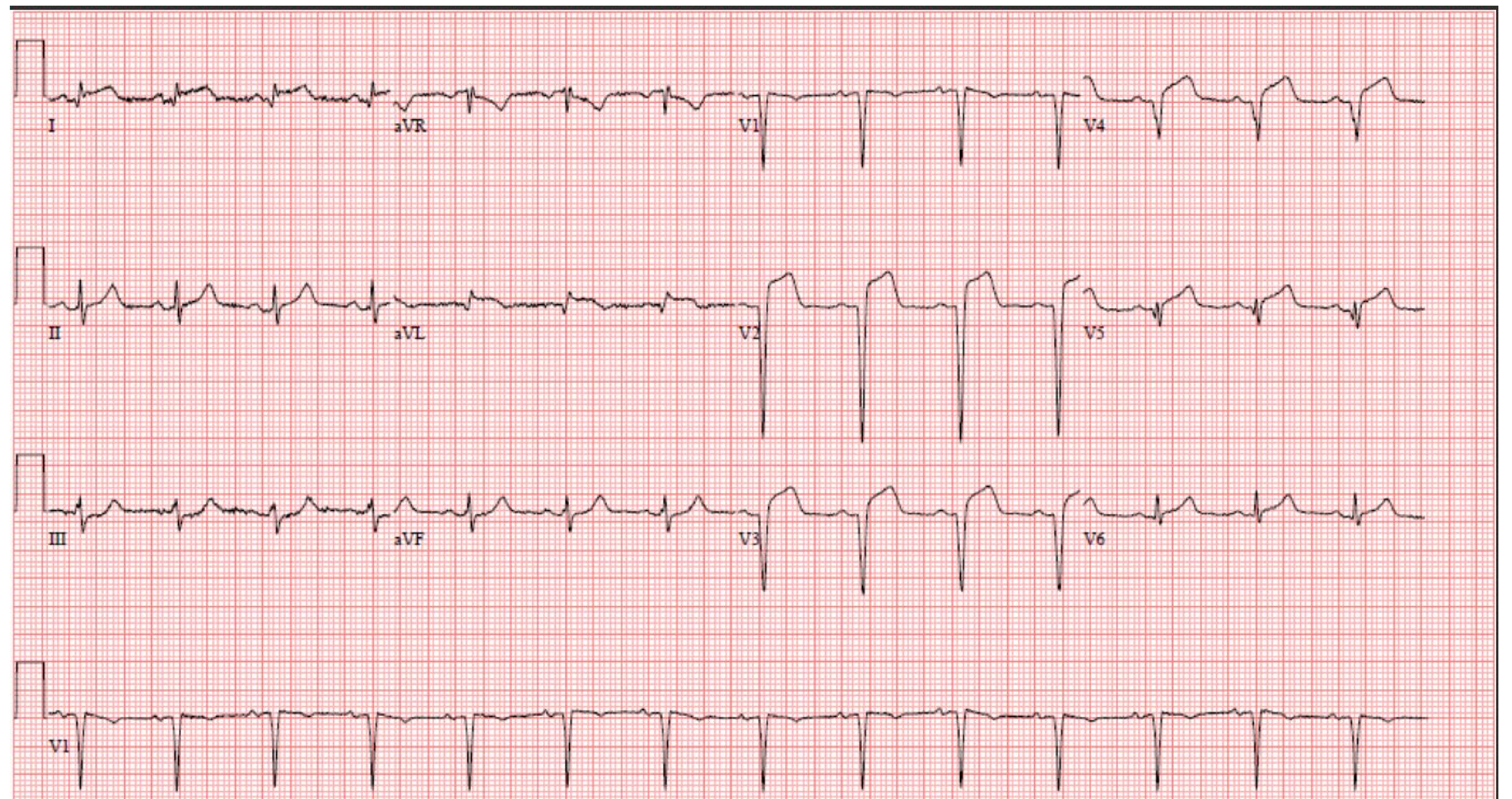
## Learning Objectives

- 1) Recognize peri-infarct pericarditis in an era of reperfusion and revascularization
- 2) Discuss treatment challenges for treating peri-infarct pericarditis and how they differ from acute pericarditis and acute coronary syndrome.

## Case Presentation

47-year-old man with past medical history of cigarette smoking >20 years was sent to emergency room from urgent care clinic with complaints of chest pain that radiates from his left chest wall to his left arm and shoulder, exacerbated when lying down and with deep inspiration and was relieved when sitting upright for 1 day duration. Family history was significant for a brother who had a myocardial infarction at age 38.

Physical exam was negative for chest tenderness, murmurs, rubs or gallops and respiratory exam was clear to auscultation. Electrocardiogram (ECG) revealed diffuse ST-elevations and poor R wave progression. Troponin were significantly elevated >22,973 ng/L and CK was 3161 U/L. Subsequent transthoracic echocardiogram revealed apical wall motion abnormalities, decreased ejection fraction 35-45% and no pericardial effusion. Cardiac catheterization revealed 100% occlusion in proximal left anterior descending artery with significant thrombus/plaque burden. Two drug-eluting stents were placed in the LAD. Post-catheterization, the patient continued to have severe pain and EKG ST-elevations remained prominent. Due to persistent diffuse ST elevation and chest pain typical for pericarditis, the patient was diagnosed with peri-infarct pericarditis and was treated with high-dose aspirin 650mg three times daily for a 7-day course and colchicine 0.6 mg daily for 3 months. In addition to this, he was provided ticagrelor for dual antiplatelet therapy. He was discharged home 3 days later with improvement in symptoms.



|                             | Latest Ref Rng & Units | 8/26/2023 | 8/27/2023                        | 8/28/2023 | 8/29/2023 |
|-----------------------------|------------------------|-----------|----------------------------------|-----------|-----------|
| High Sensitivity Troponin I | 0 - 20 ng/L            | >22973 ↑  | >22973 ↑<br>>22973 ↑<br>>22973 ↑ | >22973 ↑  | 17,054 ↑  |

## Discussion

Patients who develop peri-infarct pericarditis (PIP) commonly present within 3 days post myocardial infarction (MI). Incidence rates of PIP and other post-MI complications have been drastically decreased in the era of percutaneous coronary intervention and reperfusion. One study out of Israel following ST-elevation MI patients between 2000 and 2013 revealed only 1.2% of patients developed PIP.

Predisposing factors for developing PIP is the location of the infarct as there is an increased number of cases observed following anterior infarcts. Additionally, patients who develop PIP typically have ejection fraction <50% and have significantly elevated troponin. While not noted in this case, pericardial effusions are common amongst cases of PIP and are associated with higher rates of mortality and morbidity.

Peri-infarct pericarditis can be challenging to treat as typically non-steroidal anti-inflammatory drugs (with the exception of aspirin) are contraindicated in setting of acute MI due to increased risk of developing post-MI complications. However, in the setting of PIP, the use of high-dose aspirin defined as 650mg every six to eight hours is recommended for symptomatic relief. While this is the recommendation of the American Heart Association, there is no data to suggest that anti-inflammatory therapy increases favorable outcomes which is contrary to that of acute pericarditis of viral or idiopathic origin. Adjunctive agents such as colchicine, acetaminophen or narcotics are only used if there is no symptomatic resolution with high-dose aspirin.

While uncommon, clinicians should consider PIP in patients with persistent severe chest pain post-MI.

## References

Nemeth, M. A., Coulter, S., & Flamm, S. D. (2003). *Pericarditis after myocardial infarction*. Texas Heart Institute journal.

Uptodate (n.d.). Pericardial complications of myocardial infarction